

# Biliary stents: models and methods for endoscopic stenting

## European Society of Gastrointestinal Endoscopy (ESGE) Technology Review

### Authors

J.-M. Dumonceau<sup>1</sup>, D. Heresbach<sup>2</sup>, J. Devière<sup>3</sup>, G. Costamagna<sup>4</sup>, U. Beilenhoff<sup>5</sup>, A. Riphaus<sup>6</sup>

### Institutions

Institutions are listed at the end of article.

### submitted

22 November 2010

### accepted after revision

7 December 2010

### Bibliography

DOI <http://dx.doi.org/10.1055/s-0030-1256315>

Published online

25 May 2011

Endoscopy 2011; 43:

617–626 © Georg Thieme

Verlag KG Stuttgart · New York

ISSN 0013-726X

### Corresponding author

J.-M. Dumonceau, MD, PhD

Service of Gastroenterology and Hepatology

Geneva University Hospitals

Rue Gabrielle-PerretGentil 4

1211 Genève 14

Switzerland

Fax: +41-22-3729366

jmdumonceau@hotmail.com

Biliary stenting is widely used to palliate malignant obstruction or to treat benign biliary diseases. Recently, the most important changes have related to self-expandable metal stents (SEMSs), which are now available in a wide variety of designs, and to treatment techniques. This article is part of a combined publication that expresses the

### Introduction

The word “stent” derives from the name of an English dentist, Charles Stent (1807–1885), who invented a compound for dental impression in 1856 [1]. This compound was then used for plastic surgery during the First World War (it served as a matrix around which to form tissue in the process of rebuilding a shattered face). “Stent” is currently used to describe hollow tubes made of plastic or of metal that are implanted into a variety of anatomical locations, most commonly vessels and urological/digestive tracts.

Biliary stents are used to facilitate the drainage of bile into the digestive tract, most frequently in the palliation of malignant biliary obstruction but also in benign conditions such as biliary fistulas or benign biliary strictures. This article is part of a publication that expresses the current view of the European Society of Gastrointestinal Endoscopy (ESGE) about biliary stenting: this technology review describes the biliary stents that are currently available for endoscopic insertion and the insertion techniques, and a clinical guideline states the evidence and recommendations regarding endoscopic biliary stenting.

### Methods

The ESGE commissioned and funded these guidelines after preliminary work from the French Society of Digestive Endoscopy [2]. For the technology review, the methodology was adapted from

current view of the European Society of Gastrointestinal Endoscopy (ESGE) about endoscopic biliary stenting: a technology review describes the stent models and stenting techniques, and a separate clinical guideline states the evidence and recommendations regarding stenting.

that used for ESGE clinical guidelines; notable differences include the absence of key questions and of recommendations [3]. Briefly, a search of the relevant literature was performed in Medline (via Pubmed), the Cochrane Library, Embase, and the internet, with search terms that always included at least “biliary” and “stent” plus words pertinent to specific topics.

The following manufacturers were contacted by the Secretariat of the ESGE to collect technical information about self-expandable metal stents (SEMSs), with a maximum of two covered and two uncovered models allowed per manufacturer: Abbott Vascular (Abbott Park, Illinois, USA), Boston Scientific (Natick, Massachusetts, USA), Conmed (Utica, New York, USA), Cook Endoscopy (Winston-Salem, North Carolina, USA), C. R. Bard (Murray Hill, New Jersey, USA), Edwards Life-science (Irvine, California, USA), ELLA-CS (Hradec Kralove, Czech Republic), ev3 Endovascular (Plymouth, Minnesota, USA), Gore Medical (Flagstaff, Arizona, U.S.A), Leufen Medical (Aachen, Germany), Medinol (Jerusalem, Israel), M.I.Tech (Seoul, Korea), Optimed (Ettlingen, Germany), Sewoon Medical (Seoul, Korea), Standard Sci-Tech (Seoul, Korea), Stentech (Seoul, Korea), Taewoong (Seoul, Korea). If there was no response, the query was repeated by the first author.

In November 2010, the manuscript was endorsed by the ESGE Governing Board. It was sent to the Editorial Board of the journal *Endoscopy* for international peer review, and the final version was approved by all authors.

## Plastic stents

### Stent characteristics

#### Shape and material

Most models of plastic stents are slightly curved to fit the contour of the common bile duct (CBD) and to prevent stent migration; S-shaped stents are specifically designed for draining the left biliary tree and pigtail stents are also available, but these latter models are rarely used in the bile ducts (● Fig. 1).

Sideholes are present at both ends of many stent models in order to maintain drainage if the tip of the stent becomes impacted in the biliary or digestive tract wall. As it has been suggested that these sideholes favor sludge formation [4], models without sideholes but with multiple sideflaps intended to prevent stent migration have been developed (these are known as “Tannenbaum” stents, from the German word for fir tree). The Double Layer stent is an example of the Tannenbaum design. Attempts to prolong stent patency, by the addition of an antireflux valve or by the use of different coatings on the stent surface, are being tested [5,6]. Most “plastic” stents are made of polyethylene, Teflon, or polyurethane. Polyethylene stents become malleable (in other words, their shape may be changed) when immersed in boiling water; they are softer than Teflon stents.

#### Stent diameters

The diameter of plastic biliary stents is measured in French (Fr), a unit that corresponds to one third of a millimeter. Standard external diameters of plastic biliary stents are 7.0, 8.5, 10.0, and 11.5 Fr; it would be difficult or impossible to introduce larger stents through most standard therapeutic duodenoscopes with working channels that measure 4.2 mm in diameter.

#### Stent lengths


Standard plastic stent models are available in lengths ranging between 5 and 18 cm but custom-made stents may be ordered from some manufacturers (longer models may be useful in liver transplant recipients). Of note, the stated length usually indicates the distance between the proximal and distal flaps of the stent, not the entire stent length, but this is not true for all models.

## Technique of plastic stent insertion

### Material

This includes the following:

- ▶ **Radiopaque guide wire.** The numerous available models have been described in two recent technological evaluations [7,8]. The most popular “hybrid” models have a hydrophilic tip to facilitate passage of tight or tortuous strictures and a stiffer shaft to provide good “trackability.” Short-wire systems are available from three manufacturers, Boston-Scientific, Cook Endoscopy, and Olympus (Tokyo, Japan). These systems include a locking mechanism to prevent the wire from slipping during exchange procedures and a short wire (185–270 cm in length as compared with the usual 400–460 cm). In two randomized controlled trials (RCTs) some of these systems allowed significant reduction in the time needed for device exchange and for stent insertion compared with traditional long-wire devices [9,10]. One of these systems (Fusion; Cook Endoscopy) also allows for intraductal exchange (i.e., removing a catheter while leaving the supporting guide wire in the bile ducts), a characteristic that may facilitate insertion of multiple plastic stents [11].



**Fig. 1** Plastic biliary stents commonly used or found to be superior to other models in randomized controlled trials. **a** Cotton-Leung stent, made of polyethylene with proximal and distal sideholes and anchoring flaps (Cook Endoscopy, Winston-Salem, North Carolina, USA); **b** S-shaped stent for drainage of the left biliary tree (EndoFlex, Voerde, Germany); **c** Double-Layer stent with no sideholes and an internal coating made of perfluoroalkoxy material to prevent bacterial adhesion (Olympus, Tokyo, Japan); **d** Marathon stent with no sideholes and a valve (arrow) designed to prevent reflux of duodenal content into the biliary tree (Cook Endoscopy). Because the valve is pliable, the Marathon stent is only available preloaded on the insertion system, unlike other models.

- ▶ **Stent insertion system.** This consists of a plastic guiding catheter equipped with radiopaque markers and a pushing catheter of the same diameter as the stent. These two catheters may be pre-assembled in a single system (single-use or reusable depending on manufacturer); using a pre-assembled system allowed a significant reduction in procedure time as compared with separate guiding and pushing catheters in an RCT [12]. Thin 7.0-Fr stents are inserted over a guide wire without a plastic guiding catheter.
- ▶ **Dilators.** Bougies or balloon catheters may be useful in the case of tight strictures.

### Methods

Plastic biliary stents are placed with their distal end protruding into the duodenum, because stent placement beyond the sphincter of Oddi rather than across it does not prolong stent patency and increases the risk of stent migration [13]. Stent length is generally selected as the shortest possible that will still ensure adequate drainage. Stents are usually positioned so that one end is finally 1–2 cm beyond the proximal extent of the biliary obstacle and the other end protrudes 1 cm into the duodenum (a long intraduodenal stent portion may cause peritoneal or retroperitoneal perforation and bleeding ulcer) [14]. Stents with sideflaps designed to prevent migration must be positioned with the flaps located beyond the obstacle and in the duodenum. If the ostium of the cystic duct is large and is located immediately above the proximal end of the biliary obstacle, it may be useful to select a longer stent to avoid the possibility that it might swing into the cystic duct.

Based on cholangiography, the adequate stent length may be measured using dedicated instruments, such as a graduated guide wire or a guiding catheter that has radiopaque graduations at 1-cm intervals [8,15], or simply by withdrawing a catheter so

that its tip moves from the desired location for the upper end of the stent down to the papilla, and using a ruler to measure the length of catheter taken out of the endoscope. Estimates using X-ray images are often inaccurate even after adjusting for radiographic magnification, particularly if some parts of the duct to be stented are located in different planes (e.g., with hilar strictures) [15].

Biliary sphincterotomy is not necessary for inserting a single plastic biliary stent or SEMS [16–20]. It is nevertheless routinely performed before stenting by some endoscopists because they think that this will facilitate stent exchange during follow-up, or if more than one biliary stent is to be placed (e.g., because of hilar obstruction or benign biliary stricture). If endoscopic biliary sphincterotomy is performed, blended rather than pure-cut current should be used as this decreases the incidence of bleeding without affecting the incidence of pancreatitis following endoscopic retrograde cholangiopancreatography (ERCP) [21,22].

If the stricture is tight, dilation of the stricture before stenting may be useful (in case of doubt, a bougie of diameter equal to or greater than that of the intended stent may be inserted through the stricture).

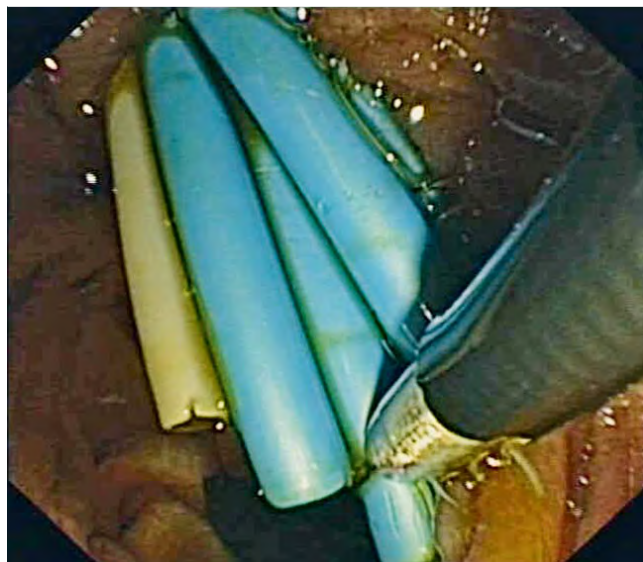
The stent is loaded the right way up onto the guiding catheter, the guiding catheter is flushed with saline, the guide wire is cleaned and moistened to reduce friction, and the whole stent insertion system (guiding catheter, stent, and pusher tube) is introduced into the working channel of the endoscope. Once inserted beyond the biliary obstacle, the guiding catheter is disconnected from the pusher tube by the assistant and the stent is progressively inserted by repeating the following maneuver: 1–2 cm of the stent is pushed out of the duodenoscope (elevator in “low” position); the elevator is closed while the assistant tightens the guiding catheter by moving apart the ends of the guiding catheter and of the pusher tube. Anticlockwise rotation and pulling of the endoscope may be helpful. During the whole procedure, the endoscope is kept close to the papilla to avoid looping of the insertion system in the duodenum. If the plastic guiding catheter is inadvertently withdrawn from inside the stent, it can be reinserted over the guide wire and stent insertion can then be continued.

If stent insertion is difficult, the duodenoscope may be placed in a “long position” and, while it is pulled back with anticlockwise rotation to straighten loops (elevator in “up” position), the guiding catheter is straightened by the assistant to advance the stent.

If the stent kinks, it may be necessary to withdraw it and to insert a new one (the guide wire may be left in place by removing the stent “over-the-wire”, using a Soehendra stent retriever or a dilation balloon inflated inside the stent).

Once the stent is thought to be in the correct position, the guide wire and the guiding catheter are withdrawn while the pusher tube is held in contact with the stent to prevent stent dislocation. An X-ray is obtained to verify that contrast medium drains through the stent. If the cystic duct is dilated, it is important to check that the upper end of the stent has not turned into that duct.

Plastic stents that are too long may be trimmed using the metal sheath of a mechanical lithotripter loaded with a snare wire. This might be done, for example, where there are multiple plastic stents and removal of the mispositioned stent could dislodge the others (● Fig. 2) [23].



**Fig. 2** Trimming a plastic biliary stent. The stent is grasped using a snare loaded into the metal sheath of a mechanical lithotripter. (A standard polypectomy snare has been dismantled by removing the wire from the plastic sheath and separating the wire from the metal tube that is inserted into the snare handle.) The snare is closed around the stent using a lithotripter rotator, in a manner similar to that used when crushing a stone with a Dormia basket.

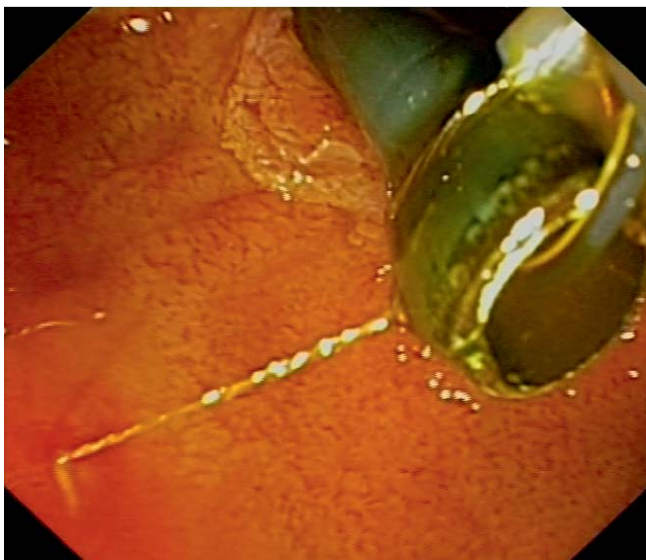
### Specific issues

**Stents with a duodenal antireflux valve** Some stents have a windsock-shaped tubular valve at the duodenal end that is intended to prolong stent patency. These are available only with a prepared insertion system because the valve is too pliable to permit easy assembly. Stent insertion is similar to that for other stents [5].

**Insertion of multiple plastic stents** Two methods may be used: previous stents may be left in place and additional ones are inserted at each ERCP (sequential multiple stenting), or all stents may be exchanged at each ERCP. A mixed approach consists of sequential multiple stenting in asymptomatic patients and stent exchange in the case of cholangitis [24,25]. Several means may be used to facilitate the insertion of multiple stents during ERCP: long stents may be inserted first to decrease the risk of proximal stent migration during further stenting; a dilation balloon may be inflated alongside stents already in place to facilitate further stenting; several guide wires may be inserted upstream from the stricture (a 10-Fr plastic stent may be inserted alongside a 0.025-inch guide wire using a standard therapeutic duodenoscope); or, if the Fusion system (Cook Endoscopy) is used, the guide wire used for stent insertion may be left upstream from the stricture after stent release and serve for insertion of the next stent.

**Stent exchange** If it is anticipated that deep biliary cannulation will be difficult after stent extraction (e.g., in a patient without prior sphincterotomy), the stent may be cannulated, a guide wire inserted through the stent, and the stent extracted through the duodenoscope using a balloon dilation catheter, a snare or a Soehendra stent retriever (● Fig. 3).

**Rendezvous procedure** If endoscopic attempts at deep biliary cannulation fail and percutaneous biliary drainage is performed, a guide wire may be introduced through the percutaneous biliary catheter into the duodenal lumen, where its tip is grasped with an endoscopic snare and pulled back up through the endoscope.



**Fig. 3** Removal of a plastic stent “over-the-wire” using a snare. After stent cannulation using a guide wire, a polypectomy snare is inserted into the working channel of the endoscope over the guide wire to grasp the stent close to its distal extremity and to remove it while the guide wire is kept in the bile duct. This technique allows the removal of stents up to 10Fr in diameter through a standard therapeutic duodenoscope; the cost is lower than using a balloon dilation catheter and the procedure is easier than using the Soehendra stent retriever.

A stent can then be inserted over the guide wire in a standard manner. A percutaneous biliary drain is usually temporarily left above the upper end of the stent, to prevent intraperitoneal leakage of bile in case of immediate stent dysfunction or to prevent obstruction of the stent because of hemobilia.

**Proximal biliary stent migration** This complication may occur during stent insertion or during follow-up. A review of the four largest retrospective case series of proximal biliary stent migration indicates that migrated stents were retrieved at ERCP in 90% of 155 patients [26–29]. Migrated stents were most often retrieved using a grasping basket (36% of cases). Inflation of a balloon extraction catheter alongside or above the stent, cannulation of the stent, or seizing it with a rat-tooth forceps were also used; each of these techniques contributed 15% of successful removals. If the stent has migrated upstream from a stricture, then balloon dilation of the stricture is usually required.

### Self-expandable metal stents

Compared with their plastic counterparts, self-expandable metal stents (SEMSs) present the advantage of expanding to a much larger diameter than the working channel of the endoscope used for insertion, thus enabling longer patency. After removal of the constraining sheath, a SEMS expands and usually reaches its nominal length and diameter within a few hours or days (the process can be accelerated by inflating a dilation balloon inside the SEMS, but this is not essential for full stent expansion). Disadvantages of SEMSs include their higher cost and that removability is not a standard feature.

## SEMS characteristics

### Shape and material

All biliary SEMS are made of metal alloys such as nitinol or Elgiloy; either a mesh is cut from a metal cylinder or metal wires are braided. The main features that differentiate the different types of SEMS are price, shortening ratio, radiopacity, covering, radial force, flexibility, size of the open cells of the mesh, anchoring mechanisms, and design of the ends. SEMS models have undergone considerable development in the last decade: out of five types in use 10 years ago, only a single one is still available [30]. The characteristics of a selection of endoscopic biliary SEMS are summarized in **Tables 1** and **2**.

In vitro measurements of radial expansion force and of flexibility have shown markedly different results between SEMS, including for covered and uncovered models of otherwise identical SEMS [31]. A high radial expansion force might be preferable, as, with uncovered Wallstents, long-term patency was higher if expansion of the SEMS reached 70% at 24 hours [32]; a high flexibility is particularly important in some locations such as the left intrahepatic ducts (one of the least flexible SEMS is the Wallstent) [31]. During self-expansion, SEMS shorten by 0%–50%; SEMS with a low shortening ratio are preferable in some circumstances (e.g. long SEMS in long tight strictures) but they may be associated with jerky deployment.

Large open cells in the mesh may allow tissue to protrude into the SEMS lumen, making it ineffective for biliary drainage either immediately after insertion or during follow-up [33–35]. Most SEMS have identical mesh cell sizes along their whole length, but some models, designed for hilar strictures, have a section with larger cells in order to facilitate the passage of instruments through the mesh at this point.

The radiopacity of the alloy used for SEMS construction may be high enough to provide adequate radiological visibility along the whole length of the stent (e.g., with the Wallstent); if it is not, radiopaque markers are used to depict SEMS contours but this may be less practical.

With covered SEMS, antimigration mechanisms are particularly important; these may include flared ends or external fins, but the latter frequently cause ulcers of the bile duct wall [36].

The distal end of the SEMS may cause bleeding or perforation if the wires are sharp and not fused (e.g., in the Wallstent); most recent models have soft ends and some have a lasso to facilitate removal of the SEMS.

Most recent nitinol SEMS models are marketed as “magnetic resonance-compatible”; older models made of Elgiloy may also be imaged at magnetic resonance although visualization of the stent lumen may be problematic [37].

### Nominal SEMS size and the delivery catheter

Most biliary SEMS models are available in several nominal lengths, generally between 4 cm and 10 cm with a nominal diameter of 10 mm, although slimmer or longer models are available from some manufacturers. Biliary SEMS are provided in a constraining sheath, mounted on a delivery catheter that accepts a guide wire measuring up to 0.035 inches in diameter; some models are compatible with short-wire systems. The diameter of the complete assembly ranges between 5.0 Fr (some Leufen stents) and 10.5 Fr (some Shim-Hanaro stents). A thin delivery catheter may be advantageous to facilitate the passage of strictures without prior dilation or for specific purposes such as the simultaneous deployment of two SEMS in the hilum. The diameter of the delivery catheter is larger for the covered model of a SEMS

**Table 1** Selection of biliary uncovered self-expandable metal stents (SEMSs) for endoscopic insertion.

	<b>Bonastent</b>	<b>Aixstent (Braided)</b>	<b>Aixstent (Laser cut)</b>	<b>Nitinella Plus</b>	<b>Niti-S D-type</b>	<b>Niti-S S-type</b>	<b>Wallflex</b>	<b>Zilver</b>
Material	Nitinol	Nitinol	Nitinol	Nitinol	Nitinol	Nitinol	Platinum	Nitinol
Construction	Braided, single wire	Braided, single wire	Laser cut	Braided, single wire	Braided, multiple wires	Braided, single wire	Braided, multiple wires	Laser cut
Diameter								
Delivery catheter	7 Fr	8.5 Fr	5 Fr or 8.5 Fr	7 Fr	8 Fr	7 Fr	8 Fr	6 Fr* or 7 Fr
Deployed stent	10 mm	8 or 10 mm	8 or 10 mm	8 or 10 mm	6, 8 or 10 mm	6, 8 or 10 mm	8 or 10 mm	6, 8 or 10 mm
Length after deployment,	40, 50, 60, 80, or 100, 120 mm	40, 60, or 80 mm	40, 60, 80, 100, or 120 mm	40, 60, 80, or 100 mm	40, 50, 60, 70, 80, 100 or 120 mm	40, 50, 60, 70, 80, 100 or 120 mm	40, 60, 80 or 100 mm	40, 60 or 80 mm
Shortening ratio†	30%	20%	0	27%	26%	37%	45%	0
Size of cells	2 × 2 mm	2 mm	5 mm	2.5 × 3 mm	3 × 4 mm	3 × 4 mm	1.7 × 2.7 mm	2.8 × 5 mm
Radiopacity	Markers	Markers	Markers	Markers	Markers	Markers	Full-length	Markers
Shape	Two flanges	Straight	Straight	Straight	Straight	Straight	Two flanges	Straight
Stent recapture	Yes, to 76% of full deployment (red marks)	No	No	Yes, to 50% of full deployment	No	No	Yes, to 80% of full deployment (fluoroscopic marks and on handle of delivery system)	No
Short-wire compatibility	No	No	No	No	No	No	Yes	Yes
Nondiscounted price in Germany, €	419	690	790	1,459	780	1,150	1,185	975
Manufacturer	Sewoon Medical, Seoul, Korea	Leufen Medical, Aachen, Germany	Leufen Medical, Aachen, Germany	ELLA-CS, Hradec Kralove, Czech Republic	Taewoong, Seoul, Korea	Taewoong, Seoul, Korea	Boston Scientific, Natick, Massachusetts, USA	Cook Endoscopy, North Carolina, USA

\*The only difference between the 6-Fr (Zilver 635) and 7-Fr (Zilver) model is the thinner, opaque, delivery catheter.

†The shortening ratio was calculated on the basis of manufacturers' data or on actual measurements by authors, for a mid-size SEMS, according to the following formula: (length of constrained SEMS – length of fully deployed SEMS)/length of constrained SEMS.

**Table 2** Selection of biliary covered self-expandable metal stents for endoscopic insertion.

	<b>Bonastent</b>	<b>Aixstent</b>	<b>Nitinella Plus</b>	<b>Niti-5</b>	<b>ComVi</b>	<b>Wallflex</b>	<b>Wallstent</b>
Material	Nitinol	Nitinol	Nitinol	Nitinol	Nitinol	Platinol	Elgiloy
Construction:	Braided, single wire	Braided, single wire	Braided, single wire	Braided, single wire	Braided, multiple wires	Braided, multiple wires	Braided, multiple wires
Diameter							
Delivery catheter	8.5 Fr	8.5 Fr or 10 Fr*	9 Fr	8 Fr	8 Fr	8.5 Fr	8 Fr
Deployed stent	10 mm	10 mm	8 or 10 mm	6, 8 or 10 mm	6, 8 or 10 mm	8 or 10 mm	8 or 10 mm
Length after deployment	40, 60, 80, or 100 mm	40, 60, or 80 mm	40, 60, 80, or 100 mm	40, 50, 60, 70, 80, 100 or 120 mm	40, 50, 60, 70, 80, 100 or 120 mm	40, 60, 80 or 100 mm	40, 60 or 80 mm
Shortening ratio†	30%	20%	27%	35%	25%	45%	45%
Radiopacity	Markers	Markers	Markers	Markers	Markers	Full-length	Full-length
Shape	Two flanges	Two flanges	Straight	Straight	Straight	Two flanges	Straight
Covering membrane							
Material	Silicone	Polyurethane	Silicone	Silicone	PTFE	Permalume	Permalume
Extent	Fully covered	Partly or fully covered	Partly covered	Fully covered	Fully covered	Partly or fully covered	Partly covered
Stent recapture	Yes, to 76% of full deployment (red marks)	No	Yes, to 50% of full deployment	No	No	Yes, to 80% of full deployment (fluoroscopic marks and on handle of delivery system)	Yes, to 80% of full deployment (fluoroscopic marks)
Short-wire compatibility	No	No	No	No	No	Yes	Yes
Distal lasso for stent repositioning	Yes	No	Yes	Yes	No	Yes	No
Non-discounted price in Germany, €	449	690	1,459	890	1,150	1,459	1,252
Manufacturer	Sewoon Medical, Seoul, Korea	Leufen Medical, Aachen, Germany	ELLA-CS, Hradec Králove, Czech Republic	Taewoong, Seoul, Korea	Taewoong, Seoul, Korea	Boston Scientific, Natick, Massachusetts, USA	Boston Scientific, Natick, Massachusetts, USA

PTFE, polytetrafluoroethylene.

\* The 8.5- and 10-Fr delivery catheters are used for partly and fully covered models, respectively.

† The shortening ratio was calculated on the basis on manufacturers' data or on actual measurements by authors, for a mid-size SEMS, according to the following formula: (length of constrained SEMS – length of fully deployed SEMS)/length of constrained SEMS.

compared with the counterpart uncovered model. The stated nominal length should be regarded with caution for SEMs that have a high shortening ratio (e.g., the Wallflex stent) because if such a SEM is deployed in a tight stenosis, its actual length will be significantly longer than expected.

Most current delivery catheters are sufficiently kink-resistant for easy SEM delivery; some are transparent and allow endoscopic visualization of the distal SEM extremity during deployment. The ability to recapture a SEM into the delivery catheter after partial deployment is useful if the SEM is deployed too distally.

### Stent covering

Stents are covered in order to prevent stent occlusion by tissue ingrowth and to facilitate SEM removal.

The covering may be made of various materials, including silicone, polyurethane, and expanded polytetrafluoroethylene; it may extend over the entire length of the stent (fully covered SEM), or small areas at the ends may be left uncovered (partly covered SEM). Some clinicians, mostly from Asia, cover the SEM themselves, using polyurethane [38].

The removability of the SEM may be important in patients with benign or malignant strictures [39,40]. The presence of an intact covering is the most important determinant for the success of SEM removal [41].

### Future development of self-expandable stents

Drug-eluting SEMs, although common in vascular applications, are not commercially available for biliary use. The concept of local drug delivery is particularly appealing for the treatment of malignant biliary obstruction, as chemotherapeutic agents may be steadily released from a SEM [42]; a single human trial has shown the feasibility of this technique [43]. Other areas of research that have been tested in animal models include radioactive SEM and bioabsorbable self-expanding stents [44,45].

### Technique of SEM insertion

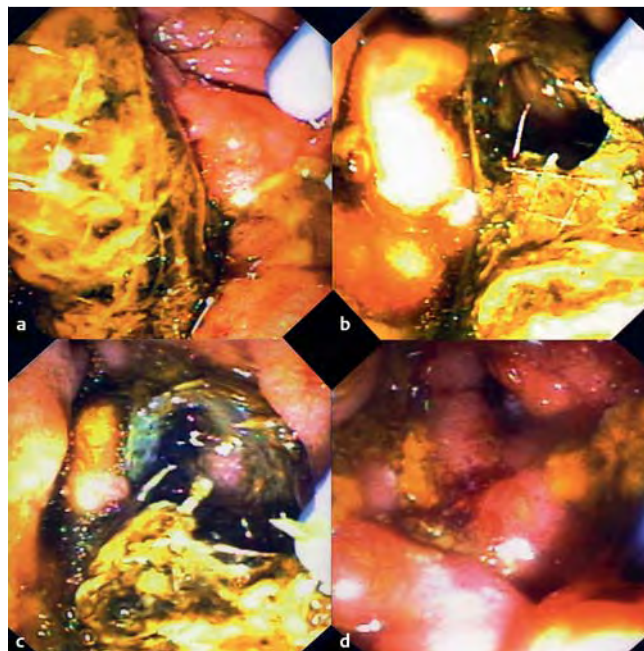
#### Equipment

As SEM are provided with a delivery catheter, no other equipment is required apart from a guide wire and, in some cases, dilators.

#### Methods

The required stent length is assessed in the same way as with plastic stents, except for covered SEM in patients with the gallbladder in situ: in such cases many authors try to avoid occluding the cystic duct ostium by inserting the stent below the ostium (or by inserting a thin plastic stent into the gallbladder but this latter approach carries a high morbidity rate) [46].

If applicable, the SEM delivery catheter and the constraining sheath are flushed with saline before the delivery catheter is advanced over the guide wire into the desired location. The SEM is deployed under fluoroscopic control by pulling back the constraining sheath, with the elevator in the low position. The position of the SEM is maintained during deployment by pulling on the delivery catheter; it can be adjusted in the distal direction by more traction on the delivery catheter or, in the proximal direction, by recapturing the SEM inside the constraining sheath (not possible with all SEM models) and advancing the delivery catheter again. SEM models with a low shortening ratio may deploy with only limited traction on the constraining sheath and require careful manipulation. After SEM delivery, the catheter is with-



**Fig. 4** Trimming a metal biliary stent. **a** Distal end of an uncovered biliary Wallstent that protruded into the duodenum and was responsible for a bleeding ulcer. **b** The stent was fenestrated using argon plasma coagulation (APC 300 combined with ICC 200 and APC1500 A probe; Erbe, Tübingen, Germany) with power set at 90 W and argon plasma flow at 1.2 L/min. For more effective heating, the probe was not applied directly against the metal wires. **c** The largely opened stent. Irrigation with water was done at regular intervals during trimming to prevent excessive heating. **d** The papillary orifice after removal of the distal stent wires; there was no significant mucosal burning.

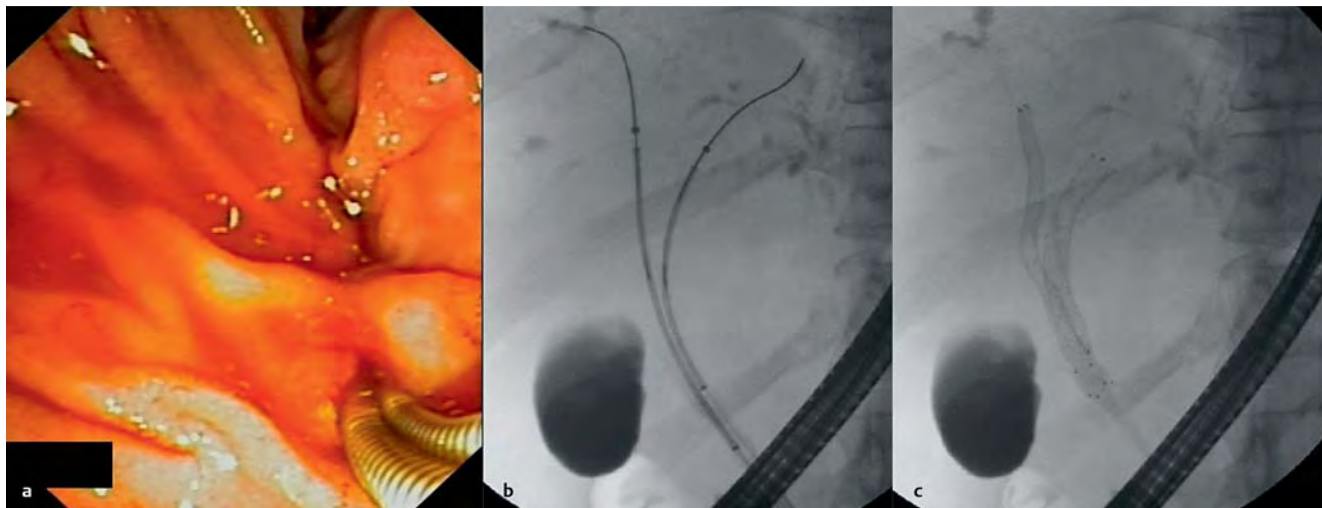
drawn, taking care to not displace the SEM with the olive at the tip of the catheter.

If the stent has been deployed too proximally, it may be useful to withdraw the delivery catheter while leaving the guide wire in place and to attempt stent repositioning using a balloon or a rat-tooth forceps. If this fails, a second SEM may be inserted to prolong the first one. If the SEM is positioned too distally with a large portion protruding into the duodenum, it may be trimmed (using argon plasma coagulation [APC] with specific settings) to prevent the development of duodenal ulcers (► **Fig. 4**) [47].

### Specific situations

**Drainage of malignant hilar strictures** In malignant hilar strictures, the hepatic sectors or sector to be drained are usually selected before the start of ERCP, based on magnetic resonance imaging (MRI) or computed tomography (CT) scan, with the aim of draining more than 50% of the liver volume [48]. As an adequate cholangiogram is usually obtained before ERCP, efforts are made to inject contrast medium only into the obstructed ducts that will be drained, for example by injecting contrast medium after the stricture of interest has been passed, or by using contrast-free cannulation techniques [49,50].

If the insertion of multiple SEMs is attempted, they can be placed in a “side-by-side” or a “stent-in-stent” (“Y”) configuration; the side-by-side configuration facilitates SEM revision [30]. In all cases, the following may be useful: to dilate both sides of the hilum using a balloon catheter (usually 6 mm in diameter); to use a long guide wire that is very stiff for stent insertion; to insert the first SEM in the left lobe (insertion in the right lobe is



**Fig. 5** Bilateral drainage of a malignant hilar stricture by simultaneous deployment of two Zilver 635 self-expandable metal stents (SEMSs) (10 × 60 mm; Cook Endoscopy). **a** Endoscopic view of the two 6-Fr delivery catheters inserted side-by-side. **b** Two unexpanded SEMSs positioned across

the stricture. **c** The two SEMSs in place after simultaneous deployment by two assistants; deployment was extremely gradual, alternating each SEMS for one third of its length up to final release.

easier); and, for drainage of the right lobe, to select a duct that is relatively straight (usually in the right paramedian sector). In the side-by-side configuration, guide wires are inserted in all of the desired ducts before SEMS delivery. After deployment of the first SEMS, inserting the second delivery system may be difficult due to impaction of the delivery catheter of the second SEMS against the first now-deployed SEMS (in fact, this may even be impossible with some stent designs, in particular with laser cut stents). Strategies to circumvent this difficulty include the following: side-by-side insertion of two delivery catheters followed by simultaneous deployment of both SEMSs (this requires the use of SEMS with delivery catheters ≤ 6 Fr) (● **Fig. 5**) [51]; a rapid SEMS insertion sequence (the delivery catheter of the second SEMS is inserted over the guide wire while the first SEMS is being deployed); having the first SEMS traverse the papilla; or inserting a temporary plastic stent [52].

Both SEMS should be positioned with their distal end in the duodenum, or at the same level in the CBD, to facilitate SEMS revision if needed.

With the stent-in-stent (Y) configuration, the second (right-hand) SEMS is inserted through the mesh of the first (left-hand) SEMS. Strategies to facilitate this procedure include the following: balloon dilation of the right hepatic duct immediately before inserting the left SEMS (to ease “through-the-mesh” cannulation of the right ducts with a hydrophilic guide wire); dilation of the cannulated SEMS mesh by means of a balloon, before inserting the right-hand SEMS; or use of a specific SEMS with a more open mesh [53,54]. Some SEMS models such as the Wallstent do not allow the stent-in-stent configuration.

Similar recommendations can be made for bilateral drainage using plastic stents. A reliable method consists of the following: inserting a 0.025-inch and a 0.035-inch guide wire in the right and the left biliary tree, respectively; dilating the right and left bile ducts; and then inserting a 8.5-Fr stent into the left biliary tree (alongside the 0.025-inch guide wire) followed by the insertion of a 10-Fr stent in the right biliary tree.

**Combined stenting in malignant biliary and duodenal obstructions** Three situations may develop, depending on the relative timing of the occurrence of biliary and duodenal obstructions:

- ▶ The duodenal stenosis develops when a biliary stent is already in place (most frequent situation, which may facilitate further biliary stenting [55]). A biliary SEMS is inserted to prevent further need of biliary drainage (unless the biliary stent already in place is a SEMS and is patent), and then the duodenal SEMS is inserted. Biliary SEMS insertion may be performed by the percutaneous route if endoscopic access to the major papilla is not possible.
- ▶ Duodenal and biliary stenoses develop simultaneously. Percutaneous biliary SEMS insertion followed by duodenal stenting may be a preferred option. If a fully endoscopic option is selected, then insertion of the duodenoscope into the second portion of the duodenum is attempted immediately after release of the uncovered duodenal SEMS and, in case of failure, again 24–48 hours later (this is to allow for complete SEMS deployment; balloon dilation of duodenal SEMS causes bleeding that may impair biliary cannulation). The mesh cells of the duodenal SEMS that are close to the major papilla may be cut by means of APC, to facilitate biliary cannulation (provided there is enough space between the duodenoscope and the SEMS mesh), or they may be moved apart after biliary cannulation, using a balloon catheter [56]; a specific duodenal SEMS with unfixed wires may also be used [57].
- ▶ The biliary stenosis develops when a duodenal SEMS is already in place (a rare situation). The techniques described above for inserting a biliary SEMS through the mesh of the duodenal SEMS, using APC or balloon dilation, may be useful if the endoscopic route is chosen.

### Acknowledgments

▼ The authors thank M. Giovannini and T. Ponchon for critical revision of the manuscript.

**Competing interests:** The authors declare no conflict of interest relevant to this publication.



## Institutions

- <sup>1</sup> Service of Gastroenterology and Hepatology, Geneva University Hospitals, Geneva, Switzerland
- <sup>2</sup> Department of Digestive Diseases, SMAD, Rennes, France
- <sup>3</sup> Department of Gastroenterology and Hepato-Pancreatology, Hôpital Universitaire Erasme, Brussels, Belgium
- <sup>4</sup> Digestive Endoscopy Unit, Policlinico A. Gemelli, Rome, Italy
- <sup>5</sup> ESGENA, Ulm, Germany
- <sup>6</sup> Department of Medicine, Ruhr University Bochum, Bochum, Germany

## References

- 1 Ring ME. How a dentist's name became a synonym for a life-saving device: the story of Dr. Charles Stent. *J Hist Dent* 2001; 49: 77–80
- 2 Arpurt J, Barrioz T, Barthelet M et al. Consensus en endoscopie digestive (CED). Les prothèses biliaires. *Acta Endosc* 2009; 39: 116–121
- 3 Dumonceau J-M, Riphaus A, Aparicio JR et al. ESGE-ESGENA-ESA Guideline: Nonanesthesiologist administration of propofol for GI endoscopy. *Endoscopy* 2010; 42: 960–974
- 4 Coene PP, Groen AK, Cheng J et al. Clogging of biliary endoprosthesis: a new perspective. *Gut* 1990; 31: 913–917
- 5 Dua K, Reddy N, Rao V et al. Impact of reducing duodenobiliary reflux on biliary stent patency: an in vitro evaluation and a prospective randomized clinical trial that used a biliary stent with an antireflux valve. *Gastrointest Endosc* 2007; 65: 819–828
- 6 Seitz U, Block A, Schaefer A-C et al. Biliary stent clogging solved by nanotechnology? In vitro study of inorganic-organic sol-gel coatings for teflon stents. *Gastroenterology* 2007; 133: 65–71
- 7 Shah RJ, Somogyi L, Petersen BT et al. Short-wire ERCP systems. ASGE Technology Committee. *Gastrointest Endosc* 2007; 66: 650–657
- 8 Somogyi L, Chuttani R, Croffie J et al. Guidewires for use in GI endoscopy. *Gastrointest Endosc* 2007; 65: 571–576
- 9 Draganov PV, Kowalczyk L, Fazel A et al. Prospective randomized blinded comparison of a short-wire endoscopic retrograde cholangiopancreatography system with traditional long-wire devices. *Dig Dis Sci* 2010; 55: 510–515
- 10 Joyce AM, Ahmad NA, Beilstein MC et al. Multicenter comparative trial of the V-scope system for therapeutic ERCP. *Endoscopy* 2006; 38: 713–716
- 11 Reddy SC, Draganov PV. ERCP wire systems: the long and the short of it. *World J Gastroenterol* 2009; 15: 55–60
- 12 Lawrie BW, Pugh S, Watura R. Bile duct stenting: a comparison of the One-Action Stent introduction system with the conventional delivery system. *Endoscopy* 1996; 28: 299–301
- 13 Pedersen FM, Lassen AT, Schaffalitzky de Muckadell OB. Randomized trial of stent placed above and across the sphincter of Oddi in malignant bile duct obstruction. *Gastrointest Endosc* 1998; 48: 574–579
- 14 Saranga Bharathi R, Rao P, Ghosh K. Iatrogenic duodenal perforations caused by endoscopic biliary stenting and stent migration: an update. *Endoscopy* 2006; 38: 1271–1274
- 15 Dumonceau JM, Devière J, Delhaye M et al. A guiding catheter to facilitate accurate stent length determination. *Gastrointest Endosc* 1998; 48: 203–206
- 16 Banerjee N, Hilden K, Baron TH, Adler DG. Endoscopic biliary sphincterotomy is not required for transpapillary SEMS placement for biliary obstruction. *Dig Dis Sci* 2011; 56: 591–595
- 17 Artifon ELA, Sakai P, Ishioka S et al. Endoscopic sphincterotomy before deployment of covered metal stent is associated with greater complication rate: a prospective randomized control trial. *J Clin Gastroenterol* 2008; 42: 815–819
- 18 Mavrogiannis C, Liatos C, Papanikolaou IS et al. Biliary stenting alone versus biliary stenting plus sphincterotomy for the treatment of post-laparoscopic cholecystectomy biliary leaks: a prospective randomized study. *Eur J Gastroenterol Hepatol* 2006; 18: 405–409
- 19 Di Giorgio P, De Luca L. Comparison of treatment outcomes between biliary plastic stent placements with and without endoscopic sphincterotomy for inoperable malignant common bile duct obstruction. *World J Gastroenterol* 2004; 10: 1212–1214
- 20 Hui C-K, Lai K-C, Yuen M-F et al. Does the addition of endoscopic sphincterotomy to stent insertion improve drainage of the bile duct in acute suppurative cholangitis? *Gastrointest Endosc* 2003; 58: 500–504
- 21 Rey JF, Beilenhoff U, Neumann CS, Dumonceau JM. European Society of Gastrointestinal Endoscopy (ESGE) Guideline: the use of electrosurgical units. *Endoscopy* 2010; 42: 764–772
- 22 Dumonceau J-M, Andriulli A, Deviere J et al. European Society of Gastrointestinal Endoscopy (ESGE) Guideline: prophylaxis of post-ERCP pancreatitis. *Endoscopy* 2010; 42: 503–515
- 23 Mutignani M, Dokas S, Perri V et al. Post-insertion tailoring of plastic biliary stents: a novel technique. *Endoscopy* 2006; 38: 856
- 24 Catalano MF, Linder JD, George S et al. Treatment of symptomatic distal common bile duct stenosis secondary to chronic pancreatitis: comparison of single vs. multiple simultaneous stents. *Gastrointest Endosc* 2004; 60: 945–952
- 25 Pozsár J, Sahin P, László F et al. Medium-term results of endoscopic treatment of common bile duct strictures in chronic calcifying pancreatitis with increasing numbers of stents. *J Clin Gastroenterol* 2004; 38: 118–123
- 26 Sakai Y, Tsuyuguchi T, Ishihara T et al. Cholangiopancreatography troubleshooting: the usefulness of endoscopic retrieval of migrated biliary and pancreatic stents. *Hepatobiliary Pancreat Dis Int* 2009; 8: 632–637
- 27 Lahoti S, Catalano MF, Geenen JE, Schmalz MJ. Endoscopic retrieval of proximally migrated biliary and pancreatic stents: experience of a large referral center. *Gastrointest Endosc* 1998; 47: 486–491
- 28 Tarnasky PR, Cotton PB, Baillie J et al. Proximal migration of biliary stents: attempted endoscopic retrieval in forty-one patients. *Gastrointest Endosc* 1995; 42: 513–520
- 29 Chaurasia OP, Rauws EA, Fockens P, Huibregtse K. Endoscopic techniques for retrieval of proximally migrated biliary stents: the Amsterdam experience. *Gastrointest Endosc* 1999; 50: 780–785
- 30 Dumonceau JM, Devière J. Self-expandable metal stents. *Baillieres Best Pract Res Clin Gastroenterol* 1999; 13: 109–130
- 31 Isayama H, Nakai Y, Toyokawa Y et al. Measurement of radial and axial forces of biliary self-expandable metallic stents. *Gastrointest Endosc* 2009; 70: 37–44
- 32 Kim HS, Lee DK, Kim HG et al. Features of malignant biliary obstruction affecting the patency of metallic stents: a multicenter study. *Gastrointest Endosc* 2002; 55: 359–365
- 33 Dumonceau JM, Cremer M, Auroux J et al. A comparison of Ultraflex Diamond stents and Wallstents for palliation of distal malignant biliary strictures. *Am J Gastroenterol* 2000; 95: 670–676
- 34 Rossi P, Bezzi M, Rossi M et al. Metallic stents in malignant biliary obstruction: results of a multicenter European study of 240 patients. *J Vasc Interv Radiol* 1994; 5: 279–285
- 35 Ferlitsch A, Oesterreicher C, Dumonceau J-M et al. Diamond stents for palliation of malignant bile duct obstruction: a prospective multicenter evaluation. *Endoscopy* 2001; 33: 645–650
- 36 Sauer B, Wang A, Rehan M et al. Single operator cholangioscopy after metal stent removal: What have we learned? *Gastrointest Endosc* 2009; 69: AB142
- 37 Merkle EM, Boll DT, Weidenbach H et al. Ability of MR cholangiography to reveal stent position and luminal diameter in patients with biliary endoprosthesis: in vitro measurements and in vivo results in 30 patients. *AJR Am J Roentgenol* 2001; 176: 913–918
- 38 Isayama H, Komatsu Y, Tsujino T et al. Polyurethane-covered metal stent for management of distal malignant biliary obstruction. *Gastrointest Endosc* 2002; 55: 366–370
- 39 Kahaleh M, Brock A, Conaway MR et al. Covered self-expandable metal stents in pancreatic malignancy regardless of resectability: a new concept validated by a decision analysis. *Endoscopy* 2007; 39: 319–324
- 40 Behm B, Brock A, Clarke BW et al. Partially covered self-expandable metallic stents for benign biliary strictures due to chronic pancreatitis. *Endoscopy* 2009; 41: 547–551
- 41 Familiari P, Bulajic M, Mutignani M et al. Endoscopic removal of malfunctioning biliary self-expandable metallic stents. *Gastrointest Endosc* 2005; 62: 903–910
- 42 Lee DK. Drug-eluting stent in malignant biliary obstruction. *J Hepatobiliary Pancreat Surg* 2009; 16: 628–632
- 43 Suk KT, Kim JW, Kim HS et al. Human application of a metallic stent covered with a paclitaxel-incorporated membrane for malignant biliary obstruction: multicenter pilot study. *Gastrointest Endosc* 2007; 66: 798–803
- 44 He G-J, Gao Q-Y, Xu S-H et al. 103Pd radioactive stent inhibits biliary duct restenosis and reduces smooth muscle actin expression during duct healing in dogs. *Hepatobiliary Pancreat Dis Int* 2006; 5: 595–598
- 45 Ginsberg G, Cope C, Shah J et al. In vivo evaluation of a new bioabsorbable self-expanding biliary stent. *Gastrointest Endosc* 2003; 58: 777–784

- 46 Gosain S, Bonatti H, Smith L *et al*. Gallbladder stent placement for prevention of cholecystitis in patients receiving covered metal stent for malignant obstructive jaundice: a feasibility study. *Dig Dis Sci* 2010; 55: 2406–2411
- 47 Vanbiervliet G, Piche T, Caroli-Bosc FX *et al*. Endoscopic argon plasma trimming of biliary and gastrointestinal metallic stents. *Endoscopy* 2005; 37: 434–438
- 48 Vienne A, Hobeika E, Gouya H *et al*. Prediction of drainage effectiveness during endoscopic stenting of malignant hilar strictures: the role of liver volume assessment. *Gastrointest Endosc* 2010; 72: 728–735
- 49 Singh V, Singh G, Gupta V *et al*. Contrast-free air cholangiography-assisted unilateral plastic stenting in malignant hilar biliary obstruction. *Hepatobiliary Pancreat Dis Int* 2010; 9: 88–92
- 50 Freeman ML, Overby C. Selective MRCP and CT-targeted drainage of malignant hilar biliary obstruction with self-expanding metallic stents. *Gastrointest Endosc* 2003; 58: 41–49
- 51 Nguyen-Tang T, Dumonceau JM. A new method to facilitate bilateral hepatic duct drainage: simultaneous insertion of two thin 6-Fr self-expandable metal stents. *Endoscopy* 2011; 43 Suppl 2: E24–E25 Epub 2011 Jan 26
- 52 Hookey LC, Le Moine O, Deviere J. Use of a temporary plastic stent to facilitate the placement of multiple self-expanding metal stents in malignant biliary hilar strictures. *Gastrointest Endosc* 2005; 62: 605–609
- 53 Kogure H, Isayama H, Nakai Y *et al*. Newly designed large cell Niti-S stent for malignant hilar biliary obstruction: a pilot study. *Surg Endosc* 2011; 25: 463–467 Epub 2010 Jul 3
- 54 Lee JH, Kang DH, Kim JY *et al*. Endoscopic bilateral metal stent placement for advanced hilar cholangiocarcinoma: a pilot study of a newly designed Y stent. *Gastrointest Endosc* 2007; 66: 364–369
- 55 Mutignani M, Tringali A, Shah SG *et al*. Combined endoscopic stent insertion in malignant biliary and duodenal obstruction. *Endoscopy* 2007; 39: 440–447
- 56 Topazian M, Baron TH. Endoscopic fenestration of duodenal stents using argon plasma to facilitate ERCP. *Gastrointest Endosc* 2009; 69: 166–169
- 57 Moon JH, Choi HJ, Ko BM *et al*. Combined endoscopic stent-in-stent placement for malignant biliary and duodenal obstruction by using a new duodenal metal stent (with videos). *Gastrointest Endosc* 2009; 70: 772–777