

Complications of ERCP

This is one of a series of position statements discussing the use of GI endoscopy in common clinical situations. The Standards of Practice Committee of the American Society for Gastrointestinal Endoscopy prepared this text. This document is an update of a previous ASGE publication.¹ In preparing this document, a search of the medical literature was performed using PubMed. Additional references were obtained from the bibliographies of the identified articles and from recommendations of expert consultants. When limited or no data exist from well-designed prospective trials, emphasis is given to results from large series and reports from recognized experts. Position statements are based on a critical review of the available data and expert consensus at the time that the document was drafted. Further controlled clinical studies may be needed to clarify aspects of this document, which may be revised as necessary to account for changes in technology, new data, or other aspects of clinical practice.

This document is intended to be an educational device to provide information that may assist endoscopists in providing care to patients. This position statement is not a rule and should not be construed as establishing a legal standard of care or as encouraging, advocating, requiring, or discouraging any particular treatment. Clinical decisions in any particular case involve a complex analysis of the patient's condition and available courses of action. Therefore, clinical considerations may lead an endoscopist to take a course of action that varies from this position statement.

Since its introduction in 1968, ERCP has become a commonly performed endoscopic procedure.² The diagnostic and therapeutic utility of ERCP has been well demonstrated for a variety of disorders, including the management of choledocholithiasis, the diagnosis and management of biliary and pancreatic neoplasms, and the postoperative management of biliary perioperative complications.³⁻⁵ The evolution of the role of ERCP has occurred simultaneously with that of other diagnostic and therapeutic modalities, most notably magnetic resonance imaging/MRCP, laparoscopic cholecystectomy (with or without intraoperative cholangiography), and EUS. For endoscopists to accurately assess the clinical appropriateness of ERCP, it is important to have a thorough

understanding of the potential complications of this procedure. Numerous studies have helped determine the expected rates of complications, potential contributing factors for these adverse events, and possible methods for improving the safety of ERCP. Recognition and understanding of potential complications of ERCP are vital in the acquisition of appropriate informed consent.⁶ Reported complication rates vary widely in the published literature because of differences in study design, patient population, and definitions of complications. The diagnosis and management of all complications of ERCP are beyond the scope of this document; however, general principles are discussed.

PANCREATITIS

Incidence

Pancreatitis is the most common serious ERCP complication.⁷⁻¹⁵ Although transient increase in serum pancreatic enzymes may occur in as many as 75% of patients,¹⁶ such an increase does not necessarily constitute pancreatitis. A widely used consensus definition for post-ERCP pancreatitis (PEP) is (1) new or worsened abdominal pain, (2) new or prolongation of hospitalization for at least 2 days, and (3) serum amylase 3 times or more the upper limit of normal, measured more than 24 hours after the procedure.¹⁷ By using this or similar definitions, the incidence of PEP in a meta-analysis of 21 prospective studies was approximately 3.5%¹⁸ but ranges widely (1.6%-15.7%) depending on patient selection.^{19,20} The rates of PEP in pediatric patients approach those seen in adults.²¹

Risk factors

Numerous factors have been found to correlate with the development of PEP. Some of these are patient specific (eg, age, sex, history of PEP), whereas others are related to the procedure itself (eg, pancreatic sphincterotomy, precut sphincterotomy) or endoscopist experience. Risk factors for PEP that have been studied in large, prospective multivariate analyses are summarized in Table 1.²² Risk factors can be synergistic. For example, Freeman et al⁹ demonstrated that the risk of pancreatitis in a female with a normal bilirubin level and suspected sphincter of Oddi dysfunction (SOD) is 18% compared with 1.1% for a typical low-risk patient. Risk of PEP associated with the use of a precut or access papillotomy is controversial. Factors such as endoscopist experience and timing of precut may affect the risk, although the literature is mixed.^{7,8,10,23-29} ERCP in the setting of suspected SOD is associated with

TABLE 1. Risk factors for post-ERCP pancreatitis in multivariate analyses

Balloon dilation of biliary sphincter

History of post-ERCP pancreatitis

Normal bilirubin

Pancreatic duct injection

Pancreatic sphincterotomy

Precut sphincterotomy

Suspected sphincter of Oddi dysfunction

Young age

Modified from Freeman.²²

increased risk of pancreatitis (as high as 20%-25%), irrespective of whether manometry is performed.⁹ When performed with aspiration-type catheters, manometry was not associated with an incremental increased risk of pancreatitis in multivariate analysis.^{9,30} Endoscopic papillary balloon dilation has been proposed as an alternative to endoscopic biliary sphincterotomy; however, 2 meta-analyses have shown a statistically significant increased risk of PEP with endoscopic papillary balloon dilation compared with standard sphincterotomy.^{31,32}

Methods of reducing post-ERCP pancreatitis

Recognition and understanding of risk factors for PEP have allowed endoscopists to provide a more accurate estimate of an individual's risk of PEP and to direct preventive measures in appropriate clinical situations.

Patient selection. Appropriate patient selection is instrumental in reducing PEP. Other imaging modalities should first be considered for the diagnosis of common bile duct stones and pancreaticobiliary malignancy. Many of the variables identified in multivariate analyses (Table 1) can be assessed pre-procedure and should be accounted for when considering ERCP. In general, alternatives to ERCP should be considered when multiple risk factors are present and the likelihood of therapeutic intervention is low.

MRCP and EUS both have sensitivity similar to that of ERCP for the detection of many pancreaticobiliary disorders without the associated risk of pancreatitis.^{3,33-35} ERCP should be reserved for those patients with a reasonable likelihood of requiring therapeutic intervention, based on either clinical criteria (eg, cholangitis) or abnormalities identified by other imaging modalities.

Pharmacologic prophylaxis. Several agents for the pharmacologic prophylaxis of PEP have been proposed, each directed toward the interruption or amelioration of some aspect of the inflammatory cascade that accompanies and potentiates acute pancreatitis. Meta-analyses have

shown a statistically significant reduction of PEP with indomethacin or diclofenac given rectally just before ERCP or on arrival at the recovery room.³⁶⁻³⁸ Many studies were limited to high-risk patients. However, other studies of oral nonsteroidal anti-inflammatory drugs have shown no benefit.³⁹ Nitroglycerin was shown to reduce the incidence of PEP in 2 meta-analyses, but methodologic limitations and the side-effect profile of nitroglycerin hinder it from being recommended in the prevention of PEP.⁴⁰⁻⁴² Other meta-analyses have found no benefit from somatostatin, octreotide, or low osmolality contrast for the prevention of PEP.^{42,43} Finally, additional studies have shown that glucocorticoids and gabexate are ineffective in the prevention of PEP.⁴⁴⁻⁴⁶

Modifications in technique to prevent pancreatitis.

Pancreatic duct stents. Multiple prospective studies have shown the benefits of temporary pancreatic duct (PD) stents in lowering the risk and severity of PEP in high-risk populations, such as those undergoing SOD manometry, ampullectomy, pancreatic sphincterotomy, precut sphincterotomy, pancreatic brush cytology, difficult biliary cannulation, and manipulation of the PD with wires.^{47,48} In a systematic review involving 680 patients in 8 studies, pancreatitis was significantly reduced with PD stents from 19% in controls to 6%. The number needed to treat to avoid a single episode of PEP with PD stent placement was 8.⁴⁹ A cost-effectiveness analysis suggested that PD stent placement in high-risk patients may be cost-effective for the prevention of PEP.⁵⁰

Wire-guided cannulation. The use of wire-guided cannulation before contrast injection has been shown in meta-analyses to result in greater success of biliary cannulation and lower risk of PEP by avoiding the injection of contrast into the pancreas.^{51,52} Data are mixed as to whether inadvertent wire-guided cannulation of the PD is an independent risk factor for PEP.^{53,54}

Electrocautery setting. A meta-analysis of 4 studies comparing pure-cut current versus blended current in patients undergoing endoscopic biliary sphincterotomy demonstrated no statistically significant difference in the rate of PEP.⁵⁵

HEMORRHAGE

Most ERCP-associated bleeding is intraluminal, although intraductal bleeding can occur and hematomas (hepatic, splenic, and intra-abdominal) have been reported.⁵⁶⁻⁵⁸ Hemorrhage is primarily a complication related to sphincterotomy rather than diagnostic ERCP. In a meta-analysis of 21 prospective trials, the rate of hemorrhage as a complication of ERCP was 1.3% (95% CI, 1.2%-1.5%) with 70% of the bleeding episodes classified as mild.¹⁸ Hemorrhagic complications may be immediate or delayed, with recognition occurring up to 2 weeks after the procedure. The risk of severe hemorrhage (ie, requiring ≥ 5 units of blood, sur-

gery, or angiography) is estimated to occur in fewer than 1 per 1000 sphincterotomies.⁵⁹

Although sphincterotomy alone is a risk factor for hemorrhage, other factors identified in multivariate analysis include coagulopathy, the use of anticoagulants within 72 hours of sphincterotomy, the presence of acute cholangitis or papillary stenosis, the use of precut sphincterotomy, and low case volume of the endoscopist (ie, 1 sphincterotomy per week or less).^{7,8,10} Observed bleeding during the initial examination is also predictive of delayed bleeding.⁷ Neither the length of incision nor the preprocedure use of aspirin or other nonsteroidal anti-inflammatory drugs appear to be important predictors of bleeding.⁷ A large, multicenter study of 4561 patients undergoing ERCP found that the risk of post-ERCP hemorrhage was associated with hemodialysis, visible bleeding during the procedure, higher bilirubin, and the use of pure-cut current for sphincterotomy.¹⁴ Antiplatelet treatment, precut sphincterotomy, coagulopathy, and cholangitis were not associated with post-ERCP hemorrhage. The use of a microprocessor-controlled ERBE electrosurgical generator for sphincterotomy has been associated with a lower rate of endoscopically visible bleeding, but not clinically evident bleeding compared with conventional electrocautery.⁶⁰ More detailed data on the safety of various types of current are needed. Treatment of bleeding includes injection therapy with epinephrine, with or without thermal therapy, and endoscopic clips.⁶¹ ERCP with sphincterotomy is considered a higher risk procedure for bleeding, and antithrombotic therapy should be adjusted according to published guidelines.⁶²

PERFORATION

Perforation rates with ERCP range from 0.1% to 0.6%.^{7,8,10,15,63} Three distinct types of perforation have been described: guidewire-induced perforation, periampullary perforation during sphincterotomy, and luminal perforation at a site remote from the papilla.⁶³ Risk factors for perforation determined in a large retrospective study included the performance of a sphincterotomy, Billroth II anatomy, the intramural injection of contrast, prolonged duration of procedure, biliary stricture dilation, and SOD.^{10,64} However, in a more recent multicenter prospective study, only malignancy and precut access were associated with an increased risk of perforation.¹⁴ Prompt recognition of periampullary perforation and treatment with aggressive biliary and duodenal drainage (by means of nasobiliary and nasogastric tubes) coupled with broad-spectrum antibiotics can result in clinical resolution without the need for operative intervention in as many as 86% of patients.⁶⁴

The management of perforation will depend on many factors, such as the site and location, clinical status, and radiographic imaging. Early identification and expeditious management of a perforation have been shown to de-

crease associated morbidity and mortality.⁶⁵ Perforations related to endoscopy are best approached in collaboration with surgical colleagues.

INFECTION

Cholangitis

The rate of post-ERCP cholangitis is 1% or less.^{7,8,10} Risk factors identified as significant include the use of combined percutaneous-endoscopic procedures, stent placement in malignant strictures, the presence of jaundice, primary sclerosing cholangitis, low case volume, and incomplete or failed biliary drainage.⁷ In the case of malignant hilar obstruction (ie, Klatskin tumor), it is suggested that endoscopists avoid filling all intrahepatic segments and drain all intrahepatic segments that are filled with contrast.⁶⁶ Unilateral endoscopic biliary stent placement directed by previous imaging (eg, MRCP) has been shown to offer palliation of jaundice equal to bilateral placement but with less risk of cholangitis.⁶⁶⁻⁶⁸ In a study of 188 patients with inoperable malignant hilar obstruction, post-ERCP cholangitis rates were lower in patients undergoing air cholangiography (3%) compared with those who had traditional iodine contrast studies before stenting (24%).⁶⁹

Cholecystitis

Cholecystitis complicates approximately 0.2% to 0.5% of ERCPs.^{7,8} The risk appears to be correlated with the presence of stones in the gallbladder and possibly filling of the gallbladder with contrast during the examination.⁷ Additionally, placement of self-expandable metal stents may increase the risk of cholecystitis, particularly if the stent is covered and the cystic duct is obstructed.⁷⁰⁻⁷²

Prevention of infection

Prophylactic antibiotics. Two meta-analyses failed to show the benefit of routine prophylactic antibiotic use in ERCP.^{73,74} A recent retrospective analysis of 11,484 ERCPs over an 11-year time period at a single institution assessed the role of antibiotics in preventing cholangitis. Although the use of routine prophylactic antibiotics decreased from 95% of patients to 25%, the infection rate decreased from 0.48% to 0.25%. Multivariate analysis indicated that only transplant recipients undergoing biliary intervention were found to be at increased risk of infection.⁷⁶

ASGE guidelines currently recommend that antibiotic prophylaxis should be considered before an ERCP in patients with known or suspected biliary obstruction in which there is a possibility that complete drainage may not be achieved at the ERCP, such as in patients with a hilar stricture and primary sclerosing cholangitis.⁷⁵ When biliary drainage is incomplete despite an ERCP, continuation of antibiotics after the procedure is recommended. Antibiotics that cover biliary flora, such as enteric gram-negative organisms and enterococci, should be used. When biliary drainage is complete, continuation of antibiotics is not

recommended. An exception is in those patients with post-transplantation biliary strictures who are undergoing an ERCP; in these patients, continuation of antibiotics after the procedure may be beneficial, even when drainage is achieved. Antibiotic prophylaxis is not recommended in patients with biliary obstruction when it is likely that an ERCP will accomplish complete biliary drainage. Antibiotic prophylaxis is not recommended before an ERCP when obstructive biliary-tract disease is not suspected. Antibiotic prophylaxis is recommended before an ERCP in patients with communicating pancreatic cysts or pseudocysts and before transpapillary or transmural drainage of pseudocysts. Some advocate use of periprocedure antibiotics for immunocompromised patients undergoing ERCP.⁷⁶

CARDIOPULMONARY COMPLICATIONS

Significant cardiopulmonary complications are rare, occurring in 1% of cases with an associated fatality rate of 0.07% based on a meta-analysis of 12,973 patients enrolled in 14 prospective studies.¹⁸ Complications include cardiac arrhythmia, hypoxemia, and aspiration. In 1 study comparing patients older than 65 years of age with younger patients, standard cardiac risk factors and hemodynamic and electrocardiographic changes during the procedure were reported as more common in the group older than 65 years, but were not statistically significant.⁷⁷ Eight percent (8%) (6/74) of patients older than 65 years of age sustained myocardial injury, documented by cardiac troponin I elevation, compared with none (0 of 56) in the younger than 65 group. Most injury occurred during prolonged procedures (>30 minutes).⁷⁷ Cardiopulmonary problems may also arise from medications used for sedation and analgesia. Recent studies with propofol for ERCP have found this drug to have the same efficacy and safety as conventional moderate sedation medications, with fewer associated hypoxic events.⁷⁸⁻⁸¹ Additionally, ERCP can be safely performed without requiring universal intubation in patients receiving propofol-based anesthesia.⁸² Careful preoperative evaluation and collaboration with anesthesiologists for high-risk or difficult-to-sedate patients may reduce complications.⁸³ In 1 study, ERCP with capnography monitoring was associated with fewer episodes of hypoxemia and apnea compared with standard monitoring.⁸⁴ The role of sedation and anesthesia in endoscopy is reviewed in another ASGE document.⁸⁵

MORTALITY

The overall mortality rate after diagnostic ERCP is approximately 0.2%.¹⁰ Death rates after therapeutic ERCP are twice as high (0.4%-0.5% in 2 large prospective studies).^{7,10} In a large meta-analysis, overall ERCP-specific mortality was 0.33% (95% CI, 0.24%-0.42%).¹⁸ Death may occur from any of the complications described previously. The mor-

tality rate must be considered in the light of the underlying indication for ERCP and patient comorbidity.

MISCELLANEOUS COMPLICATIONS

A wide variety of additional complications have been reported. These include ileus, antibiotic-related diarrhea, hepatic abscess formation, pneumothorax/pneumomediastinum, perforation of colonic diverticula, duodenal hematoma, portal venous air, and impaction of therapeutic devices, such as stone retrieval baskets.^{8,10} Pseudocysts may become infected, and filling of pseudocysts in the absence of subsequent drainage should be avoided, if possible.

Numerous complications of ERCP-placed stents have also been described, including stent migration, stent occlusion, perforation, liver abscess, acute cholecystitis, injury to the biliary duct or PD and compression of adjacent organs.⁸⁵ Stent placement in the PD has been associated with the development of ductal irregularity (36%-49%), side branch dilation (16%), and stricture development (18%-16%), all of which can mimic chronic pancreatitis.⁸⁶⁻⁸⁸ PD stent size, composition, and duration of placement may all influence the incidence of these changes, which are not clinically relevant in all cases.⁸⁹

CONCLUSION

Complications are inherent in the performance of endoscopic procedures and more so for ERCP. Knowledge of potential ERCP complications, their expected frequency, and the risk factors for their occurrence may help to recognize and to minimize the incidence and severity of complications. Endoscopists are expected to carefully select patients for the appropriate intervention, be familiar with the planned procedure and available technology, and be prepared to manage any adverse events that may arise. Once a complication occurs, early recognition and prompt intervention may minimize the morbidity and mortality associated with that complication. Review of complications as part of a continuing quality improvement process may serve to educate endoscopists, help to reduce the risk of future complications, and improve the overall quality of ERCP.⁹⁰⁻⁹²

DISCLOSURE

The following authors disclosed financial relationships relevant to this publication: Dr Evans: consultant to Cook Medical; Dr Decker: consultant to Facet Biotechnology. All other authors disclosed no financial relationships relevant to this publication.

Abbreviations: PD, pancreatic duct; PEP, post-ERCP pancreatitis; SOD, sphincter of Oddi dysfunction.

REFERENCES

1. Mallery JS, Baron TH, Dominitz JA, et al. Complications of ERCP. *Gastrointest Endosc* 2003;57:633-8.
2. McCune WS, Shorb PE, Moscovitz H. Endoscopic cannulation of the ampulla of Vater: a preliminary report. *Ann Surg* 1968;167:752-6.
3. Maple JT, Ben-Menachem T, Anderson MA, et al. The role of endoscopy in the evaluation of suspected choledocholithiasis. *Gastrointest Endosc* 2010;71:1-9.
4. Baron TH, Mallery JS, Hirota WK, et al. The role of endoscopy in the evaluation and treatment of patients with pancreaticobiliary malignancy. *Gastrointest Endosc* 2003;58:643-9.
5. Costamagna G, Shah SK, Tringali A. Current management of postoperative complications and benign biliary strictures. *Gastrointest Endosc Clin N Am* 2003;13:635-48, ix.
6. Zuckerman MJ, Shen B, Harrison ME 3rd, et al. Informed consent for GI endoscopy. *Gastrointest Endosc* 2007;66:213-8.
7. Freeman ML, Nelson DB, Sherman S, et al. Complications of endoscopic biliary sphincterotomy. *N Engl J Med* 1996;335:909-18.
8. Masci E, Toti G, Mariani A, et al. Complications of diagnostic and therapeutic ERCP: a prospective multicenter study. *Am J Gastroenterol* 2001;96:417-23.
9. Freeman ML, DiSario JA, Nelson DB, et al. Risk factors for post-ERCP pancreatitis: a prospective, multicenter study. *Gastrointest Endosc* 2001;54:425-34.
10. Loperfido S, Angelini G, Benedetti G, et al. Major early complications from diagnostic and therapeutic ERCP: a prospective multicenter study. *Gastrointest Endosc* 1998;48:1-10.
11. Vandervoort J, Soetikno RM, Tham TC, et al. Risk factors for complications after performance of ERCP. *Gastrointest Endosc* 2002;56:652-6.
12. Christensen M, Matzen P, Schulze S, et al. Complications of ERCP: a prospective study. *Gastrointest Endosc* 2004;60:721-31.
13. Rabenstein T, Schneider HT, Bulling D, et al. Analysis of the risk factors associated with endoscopic sphincterotomy techniques: preliminary results of a prospective study, with emphasis on the reduced risk of acute pancreatitis with low-dose anticoagulation treatment. *Endoscopy* 2000;32:10-9.
14. Williams EJ, Taylor S, Fairclough P, et al. Risk factors for complication following ERCP: results of a large-scale, prospective multicenter study. *Endoscopy* 2007;39:793-801.
15. Colton JB, Curran CC. Quality indicators, including complications, of ERCP in a community setting: a prospective study. *Gastrointest Endosc* 2009;70:457-67.
16. Freeman ML, Guda NM. Prevention of post-ERCP pancreatitis: a comprehensive review. *Gastrointest Endosc* 2004;59:845-64.
17. Cotton PB, Lehman G, Vennes J, et al. Endoscopic sphincterotomy complications and their management: an attempt at consensus. *Gastrointest Endosc* 1991;37:383-93.
18. Andriulli A, Loperfido S, Napolitano G, et al. Incidence rates of post-ERCP complications: a systematic survey of prospective studies. *Am J Gastroenterol* 2007;102:1781-8.
19. Cotton PB, Garrow DA, Gallagher J, et al. Risk factors for complications after ERCP: a multivariate analysis of 11,497 procedures over 12 years. *Gastrointest Endosc* 2009;70:80-8.
20. Barthet M, Lesavre N, Desjeux A, et al. Complications of endoscopic sphincterotomy: results from a single tertiary referral center. *Endoscopy* 2002;34:991-7.
21. Cheng CL, Fogel EL, Sherman S, et al. Diagnostic and therapeutic endoscopic retrograde cholangiopancreatography in children: a large series report. *J Pediatr Gastroenterol Nutr* 2005;41:445-53.
22. Freeman ML. Adverse outcomes of ERCP. *Gastrointest Endosc* 2002;56(6 Suppl):S273-82.
23. Masci E, Mariani A, Curioni S, Testoni PA. Risk factors for pancreatitis following endoscopic retrograde cholangiopancreatography: a meta-analysis. *Endoscopy* 2003;35:830-4.
24. Huibregtse K, Katon RM, Tytgat GN. Precut papillotomy via fine-needle knife papillotome: a safe and effective technique. *Gastrointest Endosc* 1986;32:403-5.
25. Binmoeller KF, Seifert H, Gerke H, et al. Papillary roof incision using the Erlangen-type pre-cut papillotome to achieve selective bile duct cannulation. *Gastrointest Endosc* 1996;44:689-95.
26. Vandervoort J, Carr-Locke DL. Needle-knife access papillotomy: an unfairly maligned technique? *Endoscopy* 1996;28:365-6.
27. Bailey AA, Bourke MJ, Kaffes AJ, et al. Needle-knife sphincterotomy: factors predicting its use and the relationship with post-ERCP pancreatitis (with video). *Gastrointest Endosc* 2010;71:266-71.
28. Tang SJ, Haber GB, Kortan P, et al. Precut papillotomy versus persistence in difficult biliary cannulation: a prospective randomized trial. *Endoscopy* 2005;37:58-65.
29. Cennamo V, Fuccio L, Repici A, et al. Timing of precut procedure does not influence success rate and complications of ERCP procedure: a prospective randomized comparative study. *Gastrointest Endosc* 2009;69:473-9.
30. Sherman S, Troiano FP, Hawes RH, et al. Sphincter of Oddi manometry: decreased risk of clinical pancreatitis with use of a modified aspirating catheter. *Gastrointest Endosc* 1990;36:462-6.
31. Baron TH, Harewood GC. Endoscopic balloon dilation of the biliary sphincter compared to endoscopic biliary sphincterotomy for removal of common bile duct stones during ERCP: a metaanalysis of randomized, controlled trials. *Am J Gastroenterol* 2004;99:1455-60.
32. Weinberg BM, Shindy W, Lo S. Endoscopic balloon sphincter dilation (sphincteroplasty) versus sphincterotomy for common bile duct stones. *Cochrane Database Syst Rev* 2006(4):CD004890.
33. Romagnuolo J, Bardou M, Rahme E, et al. Magnetic resonance cholangiopancreatography: a meta-analysis of test performance in suspected biliary disease. *Ann Intern Med* 2003;139:547-57.
34. Dave M, Elmunzer BJ, Dwamena BA, et al. Primary sclerosing cholangitis: meta-analysis of diagnostic performance of MR cholangiopancreatography. *Radiology* 2010;256:387-96.
35. Kinney T. Evidence-based imaging of pancreatic malignancies. *Surg Clin North Am* 2010;90:235-49.
36. Elmunzer BJ, Waljee AK, Elta GH, et al. A meta-analysis of rectal NSAIDs in the prevention of post-ERCP pancreatitis. *Gut* 2008;57:1262-7.
37. Zheng MH, Xia HH, Chen YP. Rectal administration of NSAIDs in the prevention of post-ERCP pancreatitis: a complementary meta-analysis. *Gut* 2008;57:1632-3.
38. Dai HF, Wang XW, Zhao K. Role of nonsteroidal anti-inflammatory drugs in the prevention of post-ERCP pancreatitis: a meta-analysis. *Hepatobiliary Pancreat Dis Int* 2009;8:11-6.
39. Cheon YK, Cho KB, Watkins JL, et al. Efficacy of diclofenac in the prevention of post-ERCP pancreatitis in predominantly high-risk patients: a randomized double-blind prospective trial. *Gastrointest Endosc* 2007;66:1126-32.
40. Bang UC, Nojgaard C, Andersen PK, et al. Meta-analysis: nitroglycerin for prevention of post-ERCP pancreatitis. *Aliment Pharmacol Ther* 2009;29:1078-85.
41. Shao LM, Chen QY, Chen MY, et al. Nitroglycerin in the prevention of post-ERCP pancreatitis: a meta-analysis. *Dig Dis Sci* 2010;55:1-7.
42. Dumonceau JM, Andriulli A, Deviere J, et al. European Society of Gastrointestinal Endoscopy (ESGE) Guideline: prophylaxis of post-ERCP pancreatitis. *Endoscopy* 2010;42:503-15.
43. George S, Kulkarni AA, Stevens G, et al. Role of osmolality of contrast media in the development of post-ERCP pancreatitis: a meta-analysis. *Dig Dis Sci* 2004;49:503-8.
44. Zheng M, Bai J, Yuan B, et al. Meta-analysis of prophylactic corticosteroid use in post-ERCP pancreatitis. *BMC Gastroenterol* 2008;8:6.
45. Zheng M, Chen Y, Yang X, et al. Gabexate in the prophylaxis of post-ERCP pancreatitis: a meta-analysis of randomized controlled trials. *BMC Gastroenterol* 2007;7:6.
46. Bai Y, Gao J, Shi X, et al. Prophylactic corticosteroids do not prevent post-ERCP pancreatitis: a meta-analysis of randomized controlled trials. *Pancreatol* 2008;8:504-9.

47. Freeman ML. Pancreatic stents for prevention of post-endoscopic retrograde cholangiopancreatography pancreatitis. *Clin Gastroenterol Hepatol* 2007;5:1354-65.
48. Ito K, Fujita N, Noda Y, et al. Can pancreatic duct stenting prevent post-ERCP pancreatitis in patients who undergo pancreatic duct guidewire placement for achieving selective biliary cannulation? A prospective randomized controlled trial. *J Gastroenterol* 2010;45:1183-91.
49. Mazaki T, Masuda H, Takayama T. Prophylactic pancreatic stent placement and post-ERCP pancreatitis: a systematic review and meta-analysis. *Endoscopy* 2010;42:842-53.
50. Das A, Singh P, Sivak MV Jr, et al. Pancreatic-stent placement for prevention of post-ERCP pancreatitis: a cost-effectiveness analysis. *Gastrointest Endosc* 2007;65:960-8.
51. Cennamo V, Fuccio L, Zagari RM, et al. Can a wire-guided cannulation technique increase bile duct cannulation rate and prevent post-ERCP pancreatitis?: A meta-analysis of randomized controlled trials. *Am J Gastroenterol* 2009;104:2343-50.
52. Shao LM, Chen QY, Chen MY, et al. Can wire-guided cannulation reduce the risk of post-endoscopic retrograde cholangiopancreatography pancreatitis? A meta-analysis of randomized controlled trials. *J Gastroenterol Hepatol* 2009;24:1710-5.
53. Wang P, Li ZS, Liu F, et al. Risk factors for ERCP-related complications: a prospective multicenter study. *Am J Gastroenterol* 2009;104:31-40.
54. Artifon EL, Sakai P, Cunha JE, et al. Guidewire cannulation reduces risk of post-ERCP pancreatitis and facilitates bile duct cannulation. *Am J Gastroenterol* 2007;102:2147-53.
55. Verma D, Kapadia A, Adler DG. Pure versus mixed electrosurgical current for endoscopic biliary sphincterotomy: a meta-analysis of adverse outcomes. *Gastrointest Endosc* 2007;66:283-90.
56. Costa Macedo T, Maldonado R, Valente A, et al. Hemobilia in hereditary hemorrhagic telangiectasia: an unusual complication of endoscopic retrograde cholangiopancreatography. *Endoscopy* 2003;35:531-3.
57. Kingsley DD, Schermer CR, Jamal MM. Rare complications of endoscopic retrograde cholangiopancreatography: two case reports. *JLS* 2001;5:171-3.
58. McArthur KS, Mills PR. Subcapsular hepatic hematoma after ERCP. *Gastrointest Endosc* 2008;67:379-80.
59. Freeman ML. Adverse outcomes of endoscopic retrograde cholangiopancreatography: avoidance and management. *Gastrointest Endosc Clin N Am* 2003;13:775-98, xi.
60. Perini RF, Sadurski R, Cotton PB, et al. Post-sphincterotomy bleeding after the introduction of microprocessor-controlled electrosurgery: does the new technology make the difference? *Gastrointest Endosc* 2005;61:53-7.
61. Ferreira LE, Baron TH. Post-sphincterotomy bleeding: who, what, when, and how. *Am J Gastroenterol* 2007;102:2850-8.
62. Anderson MA, Ben-Menachem T, Gan SI, et al. Management of antithrombotic agents for endoscopic procedures. *Gastrointest Endosc* 2009;70:1060-70.
63. Howard TJ, Tan T, Lehman GA, et al. Classification and management of perforations complicating endoscopic sphincterotomy. *Surgery* 1999;126:658-63; discussion 64-5.
64. Enns R, Eloubeidi MA, Mergener K, et al. ERCP-related perforations: risk factors and management. *Endoscopy* 2002;34:293-8.
65. Lai CH, Lau WY. Management of endoscopic retrograde cholangiopancreatography-related perforation. *Surgeon* 2008;6:45-8.
66. Sherman S. Endoscopic drainage of malignant hilar obstruction: is one biliary stent enough or should we work to place two? *Gastrointest Endosc* 2001;53:681-4.
67. De Palma GD, Galloro G, Siciliano S, et al. Unilateral versus bilateral endoscopic hepatic duct drainage in patients with malignant hilar biliary obstruction: results of a prospective, randomized, and controlled study. *Gastrointest Endosc* 2001;53:547-53.
68. Hintze RE, Abou-Rebyeh H, Adler A, et al. Magnetic resonance cholangiopancreatography-guided unilateral endoscopic stent placement for Klatskin tumors. *Gastrointest Endosc* 2001;53:40-6.
69. Pisello F, Geraci G, Modica G, et al. Cholangitis prevention in endoscopic Klatskin tumor palliation: air cholangiography technique. *Langenbecks Arch Surg* 2009;394:1109-14.
70. Okamoto T, Fujioka S, Yanagisawa S, et al. Placement of a metallic stent across the main duodenal papilla may predispose to cholangitis. *Gastrointest Endosc* 2006;63:792-6.
71. Suk KT, Kim HS, Kim JW, et al. Risk factors for cholecystitis after metal stent placement in malignant biliary obstruction. *Gastrointest Endosc* 2006;64:522-9.
72. Fumex F, Coumaros D, Napoleon B, et al. Similar performance but higher cholecystitis rate with covered biliary stents: results from a prospective multicenter evaluation. *Endoscopy* 2006;38:787-92.
73. Harris A, Chan AC, Torres-Viera C, et al. Meta-analysis of antibiotic prophylaxis in endoscopic retrograde cholangiopancreatography (ERCP). *Endoscopy* 1999;31:718-24.
74. Bai Y, Gao F, Gao J, et al. Prophylactic antibiotics cannot prevent endoscopic retrograde cholangiopancreatography-induced cholangitis: a meta-analysis. *Pancreas* 2009;38:126-30.
75. Banerjee S, Shen B, Baron TH, et al. Antibiotic prophylaxis for GI endoscopy. *Gastrointest Endosc* 2008;67:791-8.
76. Cotton PB, Connor P, Rawls E, et al. Infection after ERCP, and antibiotic prophylaxis: a sequential quality-improvement approach over 11 years. *Gastrointest Endosc* 2008;67:471-5.
77. Fisher L, Fisher A, Thomson A. Cardiopulmonary complications of ERCP in older patients. *Gastrointest Endosc* 2006;63:948-55.
78. Wehrmann T, Kokabpick S, Lembcke B, et al. Efficacy and safety of intravenous propofol sedation during routine ERCP: a prospective, controlled study. *Gastrointest Endosc* 1999;49:677-83.
79. Vargo JJ, Zuccaro G Jr, Dumot JA, et al. Gastroenterologist-administered propofol versus meperidine and midazolam for advanced upper endoscopy: a prospective, randomized trial. *Gastroenterology* 2002;123:8-16.
80. Riphaut A, Stergiou N, Wehrmann T. Sedation with propofol for routine ERCP in high-risk octogenarians: a randomized, controlled study. *Am J Gastroenterol* 2005;100:1957-63.
81. Kongkam P, Rerknimitr R, Punyathavorn S, et al. Propofol infusion versus intermittent meperidine and midazolam injection for conscious sedation in ERCP. *J Gastrointest Liver Dis* 2008;17:291-7.
82. Cote GA, Hovis RM, Ansstas MA, et al. Incidence of sedation-related complications with propofol use during advanced endoscopic procedures. *Clin Gastroenterol Hepatol* 2010;8:137-42.
83. Lichtenstein DR, Jagannath S, Baron TH, et al. Sedation and anesthesia in GI endoscopy. *Gastrointest Endosc* 2008;68:815-26.
84. Qadeer MA, Vargo JJ, Dumot JA, et al. Capnographic monitoring of respiratory activity improves safety of sedation for endoscopic cholangiopancreatography and ultrasonography. *Gastroenterology* 2009;136:1568-76; quiz 819-20.
85. Kundu R, Pleskow D. Biliary and pancreatic stents: complications and management. *Tech Gastrointest Endosc* 2008;9:125-34.
86. Kozarek RA. Pancreatic stents can induce ductal changes consistent with chronic pancreatitis. *Gastrointest Endosc* 1990;36:93-5.
87. Smith MT, Sherman S, Ikenberry SO, et al. Alterations in pancreatic ductal morphology following polyethylene pancreatic stent therapy. *Gastrointest Endosc* 1996;44:268-75.
88. Morgan DE, Smith JK, Hawkins K, et al. Endoscopic stent therapy in advanced chronic pancreatitis: relationships between ductal changes, clinical response, and stent patency. *Am J Gastroenterol* 2003;98:821-6.
89. Lawrence C, Cotton PB, Romagnuolo J, et al. Small prophylactic pancreatic duct stents: an assessment of spontaneous passage and stent-induced ductal abnormalities. *Endoscopy* 2007;39:1082-5.
90. Quality improvement of gastrointestinal endoscopy: guidelines for clinical application. *Gastrointest Endosc* 1999;49:842-4.
91. Hasan AG, Brown WR. A model for mortality-morbidity conferences in gastroenterology. *Gastrointest Endosc* 2008;67:515-8.
92. Faigel DO, Pike IM, Baron TH, et al. Quality indicators for gastrointestinal endoscopic procedures: an introduction. *Gastrointest Endosc* 2006;63(4 Suppl):S3-9.

Prepared by:
 ASGE STANDARDS OF PRACTICE COMMITTEE
 Michelle A. Anderson, MD
 Laurel Fisher, MD
 Rajeev Jain, MD
 John A. Evans, MD
 Vasundhara Appalaneeni, MD
 Tamir Ben-Menachem, MD
 Brooks D. Cash, MD
 G. Anton Decker, MD
 Dayna S. Early, MD
 Robert D. Fanelli, MD (SAGES Representative)
 Deborah A. Fisher, MD, MHS
 Norio Fukami, MD

Joo Ha Hwang, MD
 Steven O. Ikenberry, MD
 Terry L. Jue, MD
 Khalid M. Khan, MD (NASPGAN Representative)
 Mary Lee Krinsky, DO
 Phyllis M. Malpas, RN, CGRN (SGNA Representative)
 John T. Maple, DO
 Ravi N. Sharaf, MD
 Amandeep K. Shergill, MD
 Jason A. Dominitz, MD, MHS (Chair)

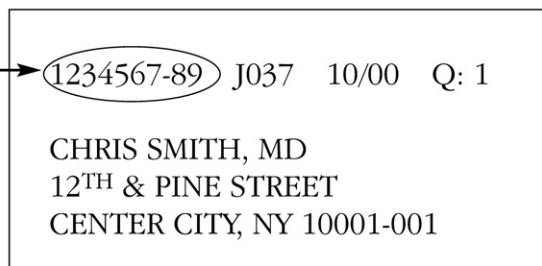
This document is a product of the ASGE Standards of Practice Committee. This document was reviewed and approved by the Governing Board of the American Society for Gastrointestinal Endoscopy.

Access to ***Gastrointestinal Endoscopy Online*** is reserved for all subscribers!

Full-text access to ***Gastrointestinal Endoscopy Online*** is available for all subscribers. ASGE MEMBER SUBSCRIBERS: To activate your individual online subscription, please visit <http://www.asge.org> and follow the instructions. NON-MEMBER SUBSCRIBERS: To activate your individual online subscription, please visit <http://www.giejournal.org> and follow the prompts to activate your *online access*. To activate your account, you will need your subscriber account/membership number, which you can find on your mailing label (*note*: the number of digits in your subscriber account number varies from 6 to 10 digits). See the example below in which the subscriber account number has been circled:

Sample mailing label

This is your Nonmember
 subscriber account number



Personal subscriptions to ***Gastrointestinal Endoscopy Online*** are for individual use only and may not be transferred. Use of ***Gastrointestinal Endoscopy Online*** is subject to agreement to the terms and conditions as indicated online.